

Maxillary Mucosal Cyst Is Not a Manifestation of Rhinosinusitis: Results of a Prospective Three-Dimensional CT Study of Ophthalmic Patients

Jeeve Kanagalingam, MA, FRCS (ORL-HNS); Kunwar Bhatia, BMedSci, FRCR; Christos Georgalas, PhD, FRCS (ORL-HNS); Wytse Fokkens, MD, PhD; Katherine Miszkiel, FRCR; Valerie J. Lund, MS, FRCS

Background: Mucosal cysts in the maxillary antrum (MMC) are a common finding in imaging of the paranasal sinuses. Their significance remains in doubt and their prevalence in the general nonrhinitic population is unknown.

Objectives: To establish the prevalence of MMCs in patients without nasal complaints and identify any association with putative causative factors. To identify any correlation between objective radiologic evidence of chronic rhinosinusitis or dental disease and the presence of cysts.

Study Design: Prospective case series.

Methods: Computed tomography (CT) images from 257 patients undergoing scans of the orbits for ophthalmic reasons were entered into this study. Patients responded to a questionnaire prior to scanning inquiring about nasal complaints, treatment for nasal disorders, previous nasal injury, allergy, asthma, recent upper respiratory tract infection, and dental root disease of the upper jaw.

Results: Overall 35.6% of patients studied had radiologic evidence of at least one maxillary mucosal cyst. There was no association between the presence of cysts and subjective or objective evidence of sinus or dental disease. Specifically, there was no correlation between the presence of cysts and the total and ostiomeatal complex Lund-Mackay radiologic scores.

Conclusions: Maxillary mucosal cysts are prevalent in nonrhinitic patients and do not reflect sinus or dental disease. Their presence should not be an indication for sinus surgery.

Key Words: Maxillary sinus, cysts, computed tomography, sinusitis.

Laryngoscope, 119:8–12, 2009

INTRODUCTION

A mucosal cyst of the maxillary sinus is a common radiologic finding. In dental screening programs, the incidence of cysts identified by panoramic radiographs may be as high as 14%.¹ When more sensitive modalities of imaging are used such as computed tomography (CT), the incidence of maxillary mucosal cysts (MMCs) is from 12.4% to 22%.^{2,3}

Mucosal cysts are benign entities and may be broadly classified as secretory or nonsecretory cysts.⁴ The latter are more common and are due to an accumulation of exudate in the sinus mucosa lifting the epithelial lining. Secretory mucosal cysts, which are less common, are due to obstruction of the mucosal glands. These are “retention” cysts, which are lined completely by epithelium.

The clinical significance of MMCs remains in doubt. Some authors assert that they represent a manifestation of inflammatory sinus disease while others refute this concept. The true incidence of MMCs in the general population is unknown. Most studies have used CT as a diagnostic tool in cohorts of patients undergoing sinus scans for presumed chronic rhinosinusitis. Harar et al.³ demonstrated that patients with mucosal cysts had a higher radiologic Lund-Mackay score (LMS) for chronic rhinosinusitis than patients without cysts. They concluded that mucosal cysts are therefore a manifestation of sinusitis. Bhattacharyya,² however, found no correlation between patency of the ostiomeatal complex and presence of mucosal cysts, and concluded that cysts do not reflect obstructive sinus phenomena.

From the Royal National Throat Nose and Ear Hospital (J.K., V.J.L.) and Moorfields Eye Hospital (K.B., K.M.), London, United Kingdom and the Department of Otorhinolaryngology, Head and Neck Surgery (C.G., W.F.), Academic Medical Center, Amsterdam, The Netherlands.

Editor's Note: This Manuscript was received May 23, 2008, and accepted for publication August 13, 2008.

Ethics approval for this study was obtained from the Whittington and Moorfields Local Research Ethics Committee.

Send correspondence to Jeeve Kanagalingam, MA, FRCS (ORL-HNS), Royal National Throat Nose and Ear Hospital, 330 Gray's Inn Road, London WC1X 8DA, United Kingdom.
E-mail: jeevekana@hotmail.com

DOI: 10.1002/lary.20037

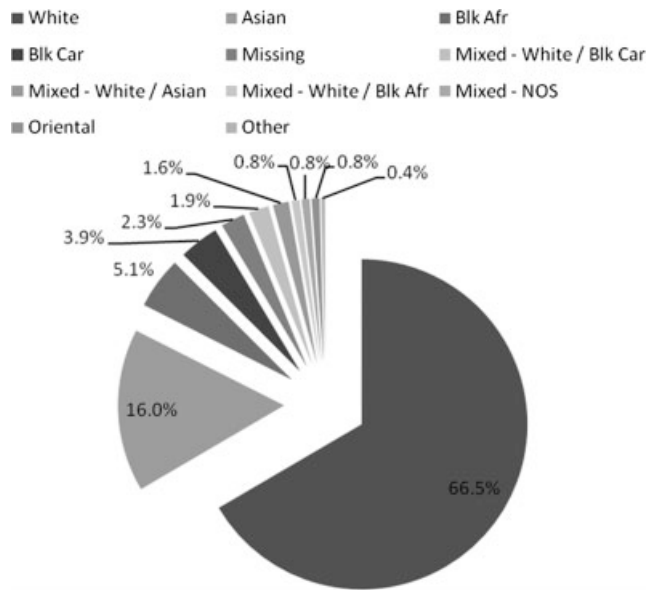


Fig. 1. Patient ethnicity.

In an attempt to study the incidence of variants in sinus anatomy amongst “normal” subjects, Jones et al. studied retrospectively 100 CT scans of the orbit taken in patients with intraorbital disease.⁵ The incidence of MMCs in this cohort of “normal” subjects was only 2%.

There is little evidence to suggest that MMCs alone cause symptoms. In a study of 40 “incidental” MMCs identified on Waters view films, Wang et al. report that 67.5% are symptomatic.⁶ Nasal obstruction—the most common symptom—was present in 52.5%. However, the prevalence of allergic rhinitis and sinusitis in this group was high at 22.5% and 20%, respectively. Hadar et al. report on a series of 60 “symptomatic” MMCs treated by endoscopic surgery.⁷ In this group, headache was reported by 63%. Following surgery and extraction of the MMCs, symptoms resolved in all but 8% of patients.

The etiology of MMCs remains a mystery. Allergy, barotrauma, rhinitis, and dental disease have all been postulated as causative factors. Berg et al. found high levels of immunoglobulins, complement, and antiproteases in cyst aspirates consistent with an inflammatory process.⁸ Significantly, levels of IgE and eosinophils were not raised, suggesting that allergy may not be a significant factor. Oral flora was cultured from cyst fluid, alluding to a possible dental cause. Indeed, dental disease has been found in up to 50% of patients with MMCs.⁹

The aim of this study was to determine:

1. The prevalence of MMCs in a population without symptoms of nasal disease.
2. The association of cysts with nasal complaints, treatment for nasal complaints, previous nasal injury, allergy, asthma, dental disease, or a recent upper respiratory tract infection (subjective evidence).
3. The association of cysts with ostiomeatal complex patency and radiologic evidence of sinus disease and dental disease (objective evidence).

TABLE I.
Responses to Questionnaire.

Comorbidity	Percentage
Nasal complaints including “hay fever”	14.4
Receiving treatment for a nasal complaint	5.8
Previous nasal trauma or fracture	4.7
Allergy	6.6
Asthma	7.0
Cough or cold in two weeks prior to scan	16.0
Dental root problems or surgery	7.0

MATERIALS AND METHODS

Between October 2007 and April 2008, 257 consecutive patients undergoing CT scans of the orbit for ophthalmological reasons were asked prospectively about nasal disease and treatment, allergy, asthma, recent respiratory tract infections and dental disease (see the Appendix).

A CT scan orbit was acquired according to the standard protocol used at the Moorfields Eye Hospital. These scans routinely included the paranasal sinuses, hence patients were not exposed to any additional radiation for the purposes of this study. A 16-slice spiral CT scanner (Somatom Sensation; Siemens, Erlanger, Germany) was used to acquire all images. Following anonymization of scans, the images were scrutinized independently by an ear, nose, throat (ENT) surgeon (J.K.) and a radiologist (K.B.) using the Leonardo Syngo workstation (Siemens, Erlanger, Germany). This allows for coronal, sagittal, and axial slices to be viewed simultaneously.

A radiologic diagnosis of a maxillary mucosal cyst was made if the following criteria were met: 1) a homogeneous dome-shaped opacity within the maxillary sinus with sharp demarcation of lateral borders; 2) absence of bony erosion; 3) absence of communication with a tooth root; and 4) a smooth, spherical outline at the free border of the cyst.

The LMS for left and right paranasal sinuses and OMCs were recorded. Mucosal cysts did not contribute to the LMS as this would introduce unacceptable bias in all our calculations. When multiple cysts were present on one side, measurements were made of the largest one. The diameter of the cyst was measured along the longest dimension. The location of the cysts was also recorded. The dental roots and any periapical lucency or dehiscence was noted.

Where discrepancy arose between the interpretations of the two observers, images were studied together and a consensus achieved.

TABLE II.
Location of Cysts Identified.

Location	Percentage (Number)
Floor	40.3 (50)
Lateral	21.0 (26)
Medial	16.9 (21)
Anterior	11.3 (14)
Posterior	5.6 (7)
Superior	4.8 (6)
Total	100 (124)

TABLE III.
Prevalence Amongst Different Ethnic Groups.

Ethnic Group	Prevalence (%)
Oriental (n = 2)	0
Asian (n = 41)	29
Black Carribean (n = 10)	30
White (n = 171)	37
Black African (n = 13)	46
Mixed (n = 11)	50

All data were entered into a database and analyzed using the Statistical Package for Social Sciences, version 14.0 for Windows software (SPSS Inc., Chicago, IL).

RESULTS

Two hundred fifty-seven consecutive patients undergoing CT scans of the orbit were prospectively recruited into this study. The mean patient age was 49.3 years (range 8–91 years) with 51.8% being female. Almost two-thirds (66.5%) of patients were white. The ethnicity of the patients studied is shown in Figure 1.

Patients were scanned for a wide variety of ophthalmologic reasons with thyroid eye disease being the most common, accounting for 35/257 (13.6%) of the scans. Four scans were performed for orbital trauma of which two involved orbital floor fractures and were excluded from subsequent analysis. None of the scans were of patients who had undergone prior orbital decompression for thyroid eye disease.

The responses to our preimaging questionnaire are summarized in Table I.

CT Results

In the cohort of patients, the median radiologic LMS for the group as a whole was 1 (mean = 2.51,

standard deviation [SD] = 3.76). The distribution of scores was not normal, with the vast majority (90%) having a score of 8 or less.

MMCs were present in 35.6% of patients, with 24.9% having a single cyst and 11.7% having two cysts. The mean maximal diameter of all 124 cysts identified was 12.2 mm (range 2.6–28.4 mm; SD = 6.2). The floor was the most common location of cysts within the six “walls” of the cuboidal maxillary antrum (40.3%). Table II summarizes the location of cysts identified.

Correlations

Patient characteristics. There was no difference in the prevalence of cysts between sexes, with 36.8% of women and 36.3% of men having at least one cyst (Pearson χ^2 , $P = .51$). Patients with MMCs were slightly younger (mean age 47.3 years vs. 50.3 years), but this was not statistically significant (Independent samples t test, $P = .215$). The wide variation in prevalence amongst the different ethnic groups (see Table III) was not statistically significant (Fisher test, $P = .89$).

Comorbidity. We looked for correlations between the presence of a cyst and comorbidities. Table IV summarizes the results of our analysis. None of the comorbidities asked about correlated with the presence of an MMC. If anything, the trend for association was negative, allaying any concerns that the study may have been underpowered.

Lund-mackay radiologic score (LMS). In the group with MMCs, the median LMS was 1 (range 1–14), and in the group without MMCs, the median score was also 1 (range 1–20).

We sought to test the theory that individuals with higher LMS scores would have more MMCs. Table V summarizes the LMS for patients with no, one, or two MMCs. When subjected to the Kruskal-Wallis test, the differences were not significant ($P = .75$).

We looked for correlation between the LMS for the ostiomeatal complex and presence of MMCs (see Table VI).

TABLE IV.
Correlation Analysis Between Comorbidities and Presence of Cysts (Subjective Evidence).

Comorbidity	Statistical Test	P Value	Correlation	Findings
Nasal complaints including “hay fever”	Pearson χ^2	.58	None	Fewer cysts in those with nasal complaints (32.4% vs. 37.3%)
Receiving treatment for a nasal complaint	Pearson χ^2	.58	None	Fewer cysts in those receiving treatment (26.7% vs. 37.2%)
Previous nasal trauma or fracture	Fisher	.22	None	Fewer cysts in those with previous trauma
Allergy	Pearson χ^2	1	None	Fewer cysts in those reporting an allergy (35.3% vs. 36.7%)
Asthma	Pearson χ^2	.02	Negative after Bonferroni adjustment for multiple comparisons	Fewer cysts in those reporting asthma (11.1% vs. 38.7%)
Cough or cold in two weeks prior to scan	Pearson χ^2	.59	None	Fewer cysts in those with recent URTI (31.7% vs. 37%)
Dental root problems or surgery	Pearson χ^2	.216	None	Fewer cysts in those with dental history (22.2% vs. 37.7%)

URTI = upper respiratory tract infection.

TABLE V.
Correlation Between Lund-Mackay Radiologic Score and Number of MMCs (Objective Evidence).

Number of MMCs	Lund-Mackay Score		
	Mean	Median	Range
0	2.57	1	0–20
1	2.59	1	0–14
2	2.03	1	0–8

MMC = maxillary antrum.

An MMC was present in 25.5% of sinuses with patent ostiomeatal complex (OMC) and in 19.4% of sinuses with a blocked OMC ($P = .497$ Pearson χ^2 , not significant).

CT evidence of dental disease. CT scans were also examined for dental disease (see Table VII). Six of 23 patients (38%) with objective evidence of dental disease had an MMC, as opposed to 87/227 (26%) of patients with no signs of dental disease. This was not statistically significant ($P = .558$, Pearson χ^2).

DISCUSSION

There is much confusion about the significance of MMCs in patients presenting to otolaryngologists with nasal symptoms. Some authors have suggested that they are a manifestation of chronic rhinosinusitis (CRS), and others have attributed symptoms such as nasal congestion and headache to these cysts.

To address the question whether MMCs are a manifestation of CRS, it would be necessary to assess the prevalence of MMCs in the general population and compare this to the prevalence in a cohort of CRS sufferers. Subjecting healthy individuals to CT scanning is not ethical given the unnecessary exposure to radiation. The best alternative is a group of patients without nasal symptoms who are having their paranasal sinuses imaged for unrelated reasons.

This study sought to use a large cohort of patients from a busy ophthalmic unit, who were having their orbits imaged by CT for ophthalmologic reasons. Jones et al. used a similar albeit smaller cohort of patients to study normal variants in sinus anatomy.⁵ In their study, patients were not asked about rhinologic symptoms and 17% of the control group had evidence of mucosal thickening. Jones et al. show a low prevalence of MMCs in both the control and CRS group of 2%. This is not in keeping with most other studies and may be a reflection of the method used to identify cysts. Three-dimensional images acquired with 1-mm slices examined on a dedi-

TABLE VI.
Correlation Between Obstructed Ostiomeatal Complex (OMC) and MMCs (Objective Evidence).

	OMC Obstructed	OMC Patent	P Value
MMC present	19.4%	25.5%	.497

MMC = maxillary antrum.

TABLE VII.
Correlation Between CT Evidence of Dental Disease and MMCs (Objective Evidence).

	Dental Disease	Normal Dentition	P Value
MMC present	38%	26%	.558

CT = computed tomography; MMC = maxillary antrum.

cated CT workstation—the method we employed—allows for a better pick-up rate.

In this study, patients were asked about nasal symptoms, nasal treatment, allergy, dental disease, a recent upper respiratory tract infection, and nasal injury prospectively before images were acquired. This allowed us to identify a “truly” asymptomatic population and correlate the presence of MMCs with a variety of putative causative factors. It may also explain why the LMS was lower than in some other studies of “normal” populations.^{10,11}

Our results show that MMCs are present in 35.6% of patients in our cohort. This is similar to published rates of MMCs in patients with chronic rhinosinusitis. We also demonstrate that nasal complaints, treatment for a nasal complaint, previous nasal injury, allergy, asthma, recent upper respiratory tract infection, and dental root disease do not increase the prevalence of MMCs. Even when an objective marker for CRS is used—in this case the radiologic LMS—no correlation was found. Although this may seem to be at odds with the findings of the study by Harar et al., one must note that in calculating the LMS, he did not account for the opacification caused by the MAC as such, and as a result, it is highly likely that a higher LM score in patients with MAC is a circular argument and reflects the presence of the cyst itself. In our study, no correlation was detected between the LMS for the ostiomeatal complex and the presence or number of cysts.

We did not inquire about a past history of chronic rhinosinusitis from our patients, and it is therefore possible that cysts noted in our group of patients may be a result of “unreported” resolved rhinosinusitis.

The issue that now remains is whether removing MMCs regardless of their significance may address some nasal symptoms in patients. Hadar’s study is flawed in that surgery to access MMCs in itself, i.e., a middle meatal antrostomy and anterior ethmoidectomy, may account for the resolution of symptoms.⁹ The ideal study would be a “sham” study, where symptomatic patients with MMCs are randomized to two groups—one in which endoscopic sinus surgery is performed but stops short of extracting MMCs and the other in which MMC extraction was completed.

CONCLUSIONS

Our study lends weight to the assertion that MMCs are neither pathologic nor a manifestation of nasal disease, and that surgery undertaken to extract MMCs is largely unnecessary.

Acknowledgments

We acknowledge the help and assistance of the radiographers in the CT scanning suite at the Moorfields Eye Hospital.

APPENDIX

Patient Questionnaire

Please answer the following questions if you agree to your scans being included in the proposed study. Read the written information sheet about this study first and ask the department staff if you are not sure about something.

To which ethnic group do you belong?

White

Mixed - White and Black Caribbean

- White and Black African

- White and Asian

- White and Oriental

Asian (Indian, Pakistani, Bangladeshi)

Black African

Black Caribbean

Oriental (Chinese, Korean, Japanese)

Indicate a more specific category here: _____

I do not wish to declare this information

Do you have any problems with your nose including "hay fever"?

Yes No

Have you received or are you receiving any treatment for a nasal complaint?

Yes No

Have you had any significant nasal injuries or fractures?

Yes No

Do you have any allergies?

Yes No

If so, what are you allergic to? _____

Do you have asthma?

Yes No

Have you had a cough or cold in the two weeks prior to your CT scan?

Yes No

Do you have any dental root problems, or have you received any treatment for dental root problems of your upper teeth?

Yes No

BIBLIOGRAPHY

1. MacDonald-Jankowski DS. Mucosal antral cysts observed within a London inner-city population. *Clin Radiol* 1994; 49:195-198.
2. Bhattacharyya N. Do maxillary sinus retention cysts reflect obstructive sinus phenomena? *Arch Otolaryngol Head Neck Surg* 2000;126:1369-1371.
3. Harar RPS, Chadha NK, Rogers G. Are maxillary mucosal cysts a manifestation of inflammatory sinus disease? *J Laryngol Otol* 2007;25:1-4.
4. Gardner DG. Pseudocysts and retention cysts of the maxillary sinus. *Oral Surg Oral Med Oral Pathol* 1984;58:561-567.
5. Jones NS, Strobl A, Holland I. A study of the CT findings in 100 patients with rhinosinusitis and 100 controls. *Clin Otolaryngol* 1997;22:47-51.
6. Wang JH, Yong JJ, Lee BJ. Natural course of retention cysts of the maxillary sinus: long-term follow-up results. *Laryngoscope* 2007;117:341-344.
7. Hadar T, Shvero J, Nageris BI, et al. Mucus retention cyst of the maxillary sinus: the endoscopic approach. *Br J Oral Maxillofac Surg* 2000;38:227-229.
8. Berg O, Carenfelt C, Sobin A. On the diagnosis and pathogenesis of intramural maxillary cysts. *Acta Otolaryngol* 1989;108:464-468.
9. Casamassimo PS, Lilly GE. Mucosal cysts of the maxillary sinus: a clinical and radiographic study. *Oral Surg Oral Med Oral Pathol* 1980;50:282-286.
10. Ashraf N, Bhattacharyya N. Determination of the "incidental" Lund score for the staging of chronic rhinosinusitis. *Otolaryngol Head Neck Surg* 2001;125:483-486.
11. Hill M, Bhattacharyya N, Hall TR, Lufkin R, Shapiro NL. Incidental paranasal sinus imaging abnormalities and the normal Lund score in children. *Otolaryngol Head Neck Surg* 2004;130:171-175.